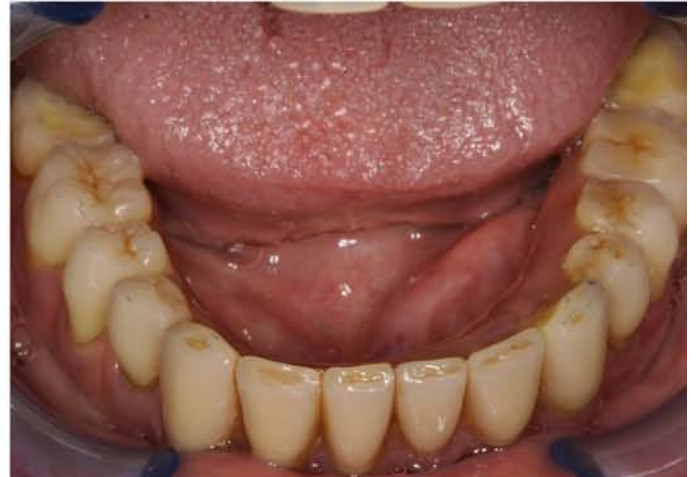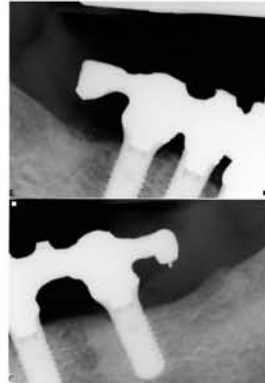
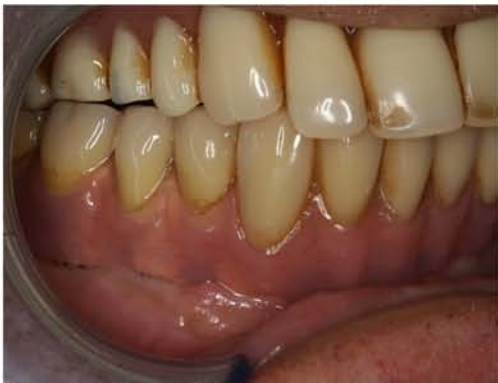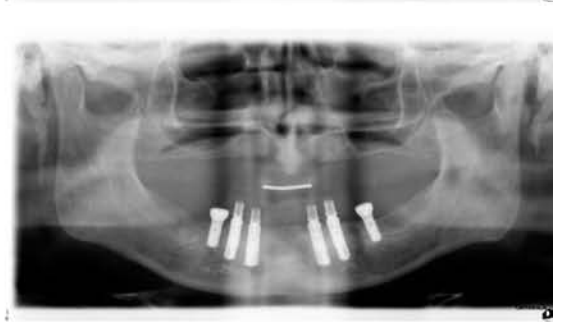
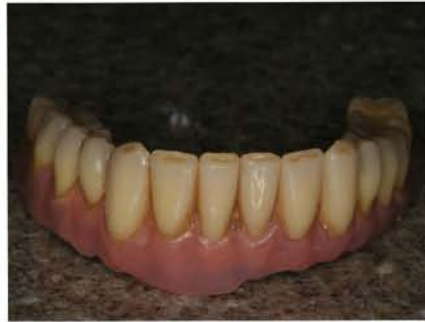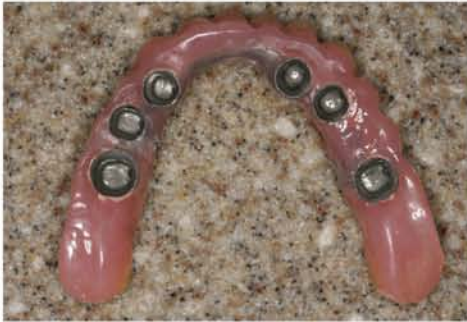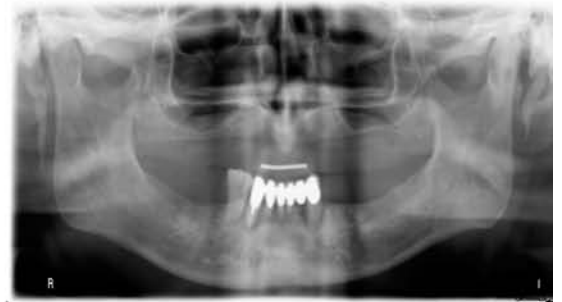


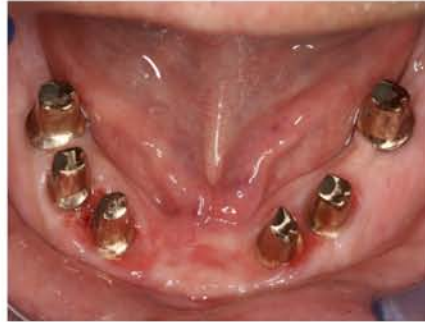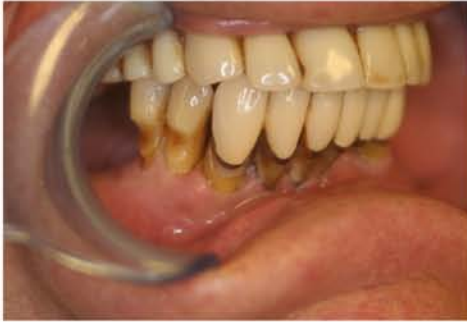Case Study 9



76 year old male: last few failing teeth extracted; six Aesthetica+ implants placed & restored with immediate provisional bridge. Eight weeks later restored with gold custom abutments, CoCr framework, Willi Geller acrylic teeth & fixed laterally into the distal abutments

aesthetica 

